

## Editorial

### Fetal lung lesions: a spectrum of disease. New classification based on pathogenesis, two-dimensional and color Doppler ultrasound

R. ACHIRON\*, J. HEGESH† and S. YAGEL‡


Departments of \*Obstetrics and Gynecology and †Pediatric Cardiology, The Chaim Sheba Medical Center, Tel-Hashomer 52621 and Sackler School of Medicine – Tel Aviv University, Tel Aviv and ‡Department of Obstetrics and Gynecology, Hadassah University Hospital – Mount Scopus, Jerusalem, Israel (e-mail: rachiron@post.tau.ac.il)

#### INTRODUCTION

Prenatal ultrasound detection of fetal anomalies has not only revolutionized management of the fetus and neonate, it has also transformed our perception of the development and natural history of congenital anomalies throughout gestation<sup>1,2</sup>. Changes in our understanding of fetal lung anomalies illustrate this concept. Ten years ago, fetal echogenic lung lesions were considered grave fetal malformations and, accordingly, textbooks of that period suggested termination of pregnancy (TOP) before fetal viability<sup>3,4</sup>. In a large series published by King's College London in 1994 summarizing 132 cases of congenital cystic adenomatoid malformation (CCAM), 44 (33%) of the cases underwent elective TOP<sup>5</sup>. Only 4 years later, another study from a very similar tertiary center reported a 10% TOP rate<sup>6</sup>.

We have also learned over the ensuing decade that some of these lesions may display dynamic changes *in utero*. For example, CCAM Type III was once thought to have a uniformly poor prognosis and as a result prenatal diagnosis would often lead to TOP. However, a proportion of cases of CCAM Type III diagnosed prenatally have been shown to resolve spontaneously. The King's College London study reported this dynamic process in 9% of its series, while a large Canadian study recently showed that 56% of cases of CCAM regressed spontaneously<sup>7</sup>. In contrast, tumor growth and hemodynamic deterioration may complicate clinical management of these lesions. To add to the confusion, the two most common pathologies of the fetal lungs, CCAM and bronchopulmonary sequestration (BPS), which seemed to be pathologically and clinically distinct, frequently overlap<sup>8</sup>, and confused terms such as 'hybrid form' and 'missing link' appear in the literature<sup>9,10</sup>.

These new and conflicting data are the tip of the iceberg of conjecture and controversy surrounding the etiology



and pathogenesis of fetal lung lesions, and classification of a specific lung anomaly according to traditional criteria has become irrelevant. It is time to revise the terminology of congenital lung lesions, not least in light of emerging *in-utero* treatment modalities for these malformations<sup>11</sup>.

We review here the latest pathological and pathogenic aspects of fetal CCAM and BPS, in an attempt to draw a parallel with prenatal ultrasound technology. Our aim is to propose a new classification system based on the pathogenesis of these malformations and their two-dimensional (2D) and color Doppler ultrasound characteristics. Elsewhere<sup>12</sup> we demonstrate the applicability of this classification system in a clinical setting.

#### PATHOLOGY AND CLASSIFICATION

##### Congenital cystic adenomatoid malformation (CCAM)

CCAM is a rare anomaly first described as a separate entity in 1949 by Chin and Tang. They reported 11 neonates; all were stillborn or very premature with anasarca<sup>13</sup>. The affected lung lobe was greatly enlarged, heavy with a tumor-like mass, often with multiple small cysts or slit-like spaces. The cysts and the spaces resembled bronchioles on microscopy and the intervening

tissue resembled very immature fetal alveoli or terminal airways. Two of the 11 cases had foci of gastric type mucoid columnar epithelium. The microscopic criteria for diagnosis of CCAM were further summarized by Kwittken and Reiner as follows<sup>14</sup>:

- Proliferation of polypoid glandular epithelium
- Proliferation of smooth muscle and elastic tissue in cyst walls
- Absence of cartilage
- Absence of inflammation
- Normal arterial and venous connections.

In order to determine the clinical and pathological spectrum of CCAM, Stocker *et al.*<sup>15</sup> collected 38 cases between 1917 and 1975, and were the first to propose three types of CCAM depending on cyst diameter and predominant cell types on histological examination, and suggested prognosis.

*Type I:* The lesion has large cysts > 2 cm diameter, frequently producing mediastinal compression. The cysts are lined by ciliated pseudostratified columnar epithelium. The walls of the cysts contain prominent smooth muscle and elastic tissue. Mucus producing cells are present in one-third of cases and cartilage in the wall is rarely seen. Relatively normal alveoli may be seen between the cysts. The prognosis is good.

*Type II:* The lesion contains multiple small cysts < 1 cm diameter, which histologically resemble dilated terminal bronchioles with mixed columnar and cuboidal linings. The area between the cysts is occupied by large, distended, alveolar-like structures. Mucus cells and cartilage are absent and, rarely, striated muscle fibers may be seen. This group has significant associated anomalies, and therefore a poor prognosis.

*Type III:* This malformation was a bulky, non-cystic lesion, typically creating a large, solid mass affecting an entire lobe or lobes and producing mediastinal shift. Histologically the mass is composed of regularly spaced, alveolus-like structures lined by ciliated cuboidal epithelium and separated by masses of alveolus-sized structures lined with non-ciliated cuboidal epithelium. This subgroup also has a very poor prognosis.

In a subsequent study Stocker expanded his classification to five types based on the site of origin of the malformation: tracheal, bronchial, bronchiolar, bronchiolar/alveolar duct and alveolar/distal acinar. Each subgroup was labeled '0' to '4', indicating the lesion's progression distally along the airway<sup>16</sup>.

### Bronchopulmonary sequestration (BPS)

BPS represents a developmental mass of non-functioning bronchopulmonary tissue that is separate from the tracheobronchial tree and receives arterial blood from the systemic circulation, which is pathognomonic for this condition. Pryce was the first to coin the term

'sequestration' (from the Latin, *sequestra*, to remove or separate) to describe this disconnected bronchopulmonary mass or cyst with an anomalous systemic arterial supply<sup>17</sup>. The classification of BPS is, however, complicated. Two subtypes were primarily defined: the intralobar mass located within the substance of a lung lobe, and extralobar BPS, which has its own pleural investment. The extralobar subtype can occur in the chest, including the pericardial sac, or in the abdomen, whereas the intralobar subtype is limited to the lung. Subsequently, in 1974 Sade showed that BPS has diverse variant forms, including bronchopulmonary and vascular related malformations. He proposed the term 'sequestration spectrum'. At one end of the spectrum is anomalous blood supply to a normal lung while at the other end is abnormal lung tissue without anomalous vascular supply<sup>18</sup>.

Between these two extremes is a large group of variant BPS that encompasses anomalies ranging from intrapulmonary sequestration to extrapulmonary sequestration with or without gastrointestinal communications, i.e. bronchopulmonary foregut malformations<sup>19</sup>.

Histologically, the extralobar BPS is a cystic or solid mass of lung parenchyma with a high ratio of mesenchyme to air space. A dilated bronchial structure with bronchial epithelium and cartilage without connection to the bronchiole system is seen. Typical to BPS is the appearance of systemic arteries with distinct elastic layers, thick media and collagenous sheaths that do not accompany bronchial structures, unlike normal pulmonary arteries. Intralobar BPS is characterized by ciliated columnar or flat epithelium that may line acquired cysts containing pus or mucus<sup>20</sup>. Owing to this difference and since it has not been observed *in utero* or in some neonates<sup>21</sup>, the intralobar variant is deemed to be an acquired phenomenon.

In the fetus, abdominal extralobar BPS may present as a retroperitoneal mass or cyst, which may lie next to the stomach or communicate with it. The arterial supply is nearly always from the descending aorta and therefore represents a persistence of primitive splanchnic arteries that supply the early foregut. Venous drainage is typically through the azygos system or the inferior vena cava; however, in about 25% of cases the venous drainage is through the pulmonary veins<sup>22</sup>.

Approximately 60% of fetuses with extralobar BPS have associated anomalies, including diaphragmatic anomalies (28%), other pulmonary anomalies (10%) and cardiac malformations (8%), while only 14% of patients with intralobar BPS have other associated anomalies<sup>23</sup>. Intra-abdominal BPS appears in approximately 10% of cases of extralobar BPS, and 90% of them occur on the left side<sup>24,25</sup>.

### PATHOGENESIS

More than 60 years following the first report by Chin and Tang<sup>13</sup>, the pathogenesis of CCAM and BPS is still unclear. Although all lung lesions appear as distinct types, their embryogenesis may overlap significantly<sup>26</sup>. Various etiologies have been suggested to describe the pathogenesis

of CCAM, among them overgrowth<sup>13</sup>, hyperplasia<sup>27</sup> and hamartoma<sup>28</sup>. However, all agreed that the defect occurred at the level of the bronchiole.

Stocker *et al.*<sup>15</sup> were the first to attempt classification of CCAM types based on embryogenesis, or the developmental stage at which the insult may have occurred. According to these authors the absence of bronchial cartilage differentiates CCAM from true bronchogenic cyst and indicates that the insult occurred before the tenth week of gestation. Type I lesion was hypothesized to stem from an insult occurring as late as 49 days postconception, while Type II probably resulted from an insult occurring earlier than 31 days postconception, since these lesions were frequently associated with other severe congenital anomalies. Type III lesions present with a pseudoglandular appearance, which may indicate maldevelopment early in embryogenesis.

Ostor and Fortune<sup>29</sup> viewed the embryogenesis of the disease differently. They stated that the presence of normal alveoli at the periphery of the lesion, with abnormal growth in the center, implies failure of canalization of the terminal bronchioles and subsequent inability to connect the conducting and respiratory elements. They conclude that the insult probably occurred later in gestation, at as late as 16–20 weeks<sup>29</sup>.

Bronchography studies and serial microscopic examination showed that bronchial atresia is the primary defect leading to the development of CCAM. The morphology of the lesion, i.e. the type of malformation, is determined by the extent of dysplastic lung growth beyond the atretic segment<sup>30</sup>.

Modern pathological studies have suggested that CCAM may arise from failed interaction between mesenchyme and epithelium during development and a lack of maturation. This observation was confirmed by immunohistological studies of CCAM cases that showed discordance between a high epithelial proliferation rate corresponding to that of mature lung, and hypovascularity corresponding to late first-trimester fetuses. Thus the discordance between vascularity and proliferation in CCAM may represent an arrest in vascular development and a loss of synchrony between stroma and epithelium<sup>31</sup>. It was suggested that in the developing lung the interaction between epithelial cells and interstitial cells is crucial to normal lung development<sup>32</sup>. The imbalance between cell proliferation and programmed cell death or apoptosis has been demonstrated in CCAM. Examination of the factors involved in cell proliferation and apoptosis can provide insight into the pathogenesis of CCAM. Some tissue growth factors have been studied as possible mediators for increased cell proliferation in CCAM. Keratinocyte growth factor was not found to mediate increased proliferation<sup>33</sup>, however glial cell-derived neurotrophic factor (GDNF) seemed to be correlated with epithelial cell proliferation while no GDNF expression was demonstrated in the stromal component of CCAM<sup>34</sup>.

Similarly, greater expression of the proliferation factor, platelet-derived growth factor BB, was found

in fetal CCAM than in age-matched normal fetal lung<sup>35</sup>. The role of apoptosis in CCAM was also analyzed. CCAM lesions requiring resection before birth had a five-fold lower apoptotic index when compared with age-matched normal fetal lung<sup>35</sup>. It can be summarized that focal asynchrony between epithelial and vascular development in CCAM leads to this congenital maldevelopment. Investigation of other factors that down-regulate apoptosis or up-regulate proliferation in CCAM may further illuminate the pathogenesis of this entity.

The pathogenesis of BPS is much more obscure than that of CCAM, and many theories have been proposed<sup>36</sup>. One states that failure of the pulmonary artery to develop fast enough to supply the whole of the growing lung leads to persistence of the embryonal systemic aortic supply. The lung area so supplied may undergo cystic and fibrous degeneration. Other authors hypothesized that insufficient pulmonary arterial blood supply may be related to the presence of systemic pulmonary collaterals<sup>22</sup>.

Although some authors attempted to view the pathogenesis of BPS as distinct from that of CCAM, they appear to have similar causes. The mechanism of their development has been described as a continuum of anomalous interactions among adjacent cells' excreted factors, to explain the overlap between them<sup>26</sup>. The microscopic resemblance of BPS and CCAM, which consists of immature or dysplastic lung tissue and the absence or reduced number of bronchial cartilage plates<sup>37</sup>, and the frequent appearance of CCAM receiving systemic arterial blood supply, indicates a common primary defect early during embryogenesis<sup>38</sup>.

The most prevalent theory states that during early development the laryngotracheal groove arises as a ventral out-pouching of the primitive foregut and migrates caudally to give rise to the bronchial tree. It is possible that in the early stages of development, when the lung bud lies in close proximity to the primitive foregut from which it is derived, some insult or adhesion in an area where these two developing organ systems are adjacent will affect both structures, resulting in a lung lesion and foregut malformation<sup>39</sup>. The observation that BPS encompasses a great variety of anomalies known also as bronchopulmonary foregut malformation and neuroenteric malformations confirms further the 'sequestration spectrum'. The frequent association of BPS with diaphragmatic hernia, gastric duplication, esophageal fistula and neuroenteric lesions supports the notion that the defect occurs early in organogenesis<sup>40</sup>.

## DIAGNOSIS

Prenatal diagnosis of fetal lung lesions relies on the appearance of space-occupying lesions or the appearance of chest masses<sup>41</sup>. Fetal lung lesions must be differentiated from congenital diaphragmatic hernia, which is diagnosed if intrathoracic stomach or bowel loops are identified. The appearance of fetal CCAM varies from predominantly solid to purely cystic masses, while BPS appears as a well-circumscribed, uniformly echogenic solid mass,

usually found in the left basal thorax<sup>42</sup>. Doppler ultrasound technology can be very useful in distinguishing between CCAM and BPS: the latter is supplied by a supporting systemic artery arising from the abdominal aorta, while CCAM is supplied by the pulmonary artery<sup>43</sup>. Intra-abdominal extrapulmonary sequestration is usually identified in the upper left abdomen as an echogenic mass, most often situated beyond the stomach. The differential diagnosis includes suprarenal masses, however the demonstration of a systemic feeding artery confirms the diagnosis of BPS.

### IN-UTERO CLASSIFICATION

Early reports on fetal lung lesions adopted the Stocker system for *in-utero* classification. The purpose of precise *in-utero* definition of fetal lung lesions is to extrapolate prognosis. Although the Stocker system was the most widely used, some major drawbacks were recognized. First, it is based on histological criteria, which cannot be applied to prenatal ultrasound technology. Second, Stocker's prognoses and outcomes were derived from the clinical data and features of 38 neonates collected from 1917 to 1975, and are no longer pertinent.

In view of these disadvantages Adzick *et al.*<sup>44</sup> suggested abandoning Stocker's three types and dividing CCAM into two major groups based on gross anatomy and ultrasound. The two categories were based on the predominant component of the lesion (cystic or solid): the macrocystic group contains single or multiple cysts  $\geq 5$  mm diameter, while the microcystic tumors are more solid and bulky with cysts  $< 5$  mm diameter. The idea of subtyping CCAM into two main groups according to the predominant lesion was not new and had been suggested previously by Ostor and Fortune<sup>29</sup> and Bale<sup>45</sup>.

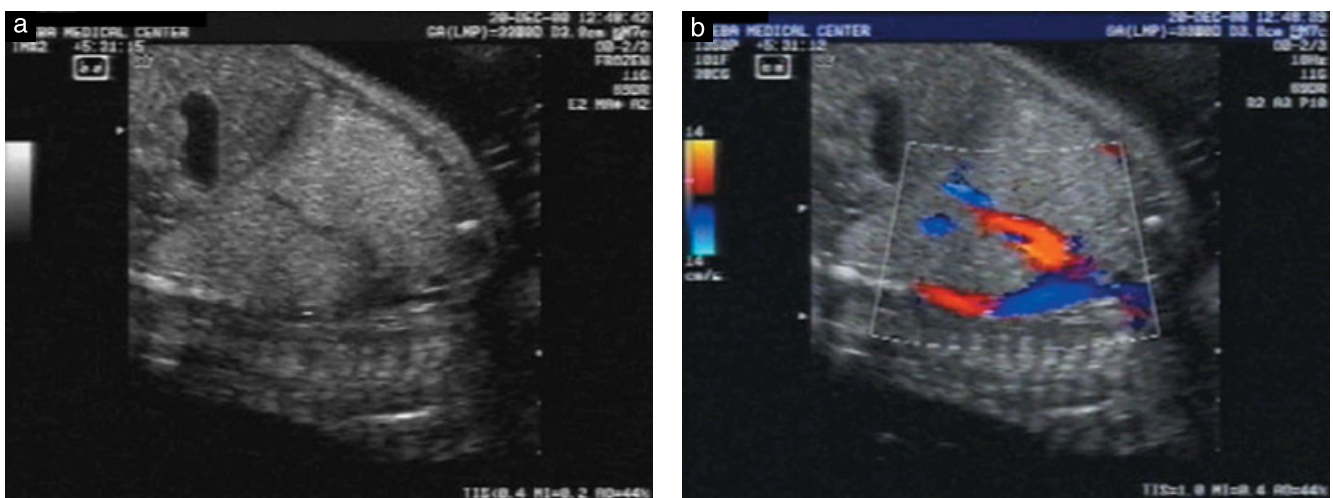
The variants are readily differentiated on prenatal ultrasound because the macrocystic type appears as fluid-filled lesions, whereas the microcystic lesions have

innumerable interfaces that return the ultrasound beam and therefore appear solid. This simple classification into two types has become the gold standard of *in-utero* CCAM diagnosis<sup>46</sup>.

### PROBLEMS WITH CURRENT DIAGNOSIS AND CLASSIFICATION

Since the original report by Adzick *et al.*<sup>44</sup>, numerous studies of the outcome and natural history of fetal lung lesions have been published<sup>47–49</sup>. However, the main problem with the current classification system is that it relies on a dichotomous definition of the lung anomaly either as CCAM or as BPS. Although the prenatal diagnosis of lung lesions is simple and Doppler studies have enhanced our ability to identify BPS, defining the exact nature of the anomaly may still prove difficult. BPS may have a sonographic appearance similar to that of CCAM (Figure 1), particularly in the microcystic subgroup. Moreover, whereas in the past histological features of CCAM had rarely been reported in BPS, no clear histological distinction exists between these two entities, and mixed histopathological findings of typical CCAM can be seen even in bronchial and laryngeal atresia<sup>50</sup>. Cystic lesions with the clinical appearance of CCAM may have systemic blood supply and BPS may have a histological appearance similar to CCAM<sup>51–53</sup>.

Recently a large pathological study found histological features compatible with CCAM Type II in approximately 50% of the cases with proven extralobar BPS. This study also showed that 11/12 (91%) prenatally diagnosed BPS cases demonstrated elements of CCAM; the authors concluded that the occurrence of CCAM in BPS is more frequent than reported in the literature<sup>8</sup>. Cass *et al.*<sup>9</sup> suggested the term 'hybrid form' to describe six cases of BPS in which the histological features were similar to those of CCAM. These findings suggest a common developmental link between BPS and CCAM<sup>10</sup>.



**Figure 1** (a) Ultrasonographic image showing a prominent left echogenic lung interpreted as microcystic congenital cystic adenomatoid malformation with a hypoechoic line of unknown origin. (b) A color Doppler image demonstrates the prominent arteriovenous shunt. The Doppler study established the diagnosis as bronchopulmonary sequestration.

These accumulated data regarding the exact definition of fetal lung lesions make prenatal counseling very difficult and postnatal management uncertain<sup>54</sup>, particularly since prognosis is related to lesion classification, and those with supposed poor prognosis (the microcystic group) may resolve spontaneously *in utero*<sup>47,48,55</sup>.

## A UNIFIED CONCEPT FOR CONGENITAL LUNG MALFORMATION AND ITS CLINICAL IMPLICATIONS

As has been discussed, congenital malformations of the lung are an ill-defined group of lesions. The present state of our knowledge on fetal lung masses indicates that the traditional classification of BPS and CCAM is insufficient to provide definitive information regarding the pathogenesis and prognosis in each individual case. Since in many instances the clinical and morphological features of both CCAM and BPS show considerable overlap, a unifying concept of their pathogenesis and classification was proposed. In 1969, Culliner proposed viewing the three entities, i.e. congenital bronchial cystic disease, sequestration and congenital bronchiectasis, as a variant of a single primary complex of bronchovascular anomalies<sup>56</sup>. Buntain *et al.* later suggested that all congenital lung lesions should be considered as one clinical group<sup>57</sup>. Demos and Teresi<sup>58</sup> suggested in 1975 grouping the possible etiologies for congenital lung malformations. Heitzman stated still further that although the terminology of congenital lung malformations suggested that these are discrete entities, their morphological characteristics overlap, thus supporting the notion that they stem from a common embryological event<sup>59</sup>.

Until the late 1980s, no concerted attempt was made to clarify the pathogenesis or classification of congenital lung lesions; most classification systems in the medical literature were based on histological findings<sup>15,16</sup>. Clements and Warner<sup>60</sup> were the first to suggest a model, based on original research, centered on a rational sequence of events in lung development, known as the 'wheel' theory. This model helped elucidate and simplify the classification of congenital lung anomalies. The authors based their theory on the assumption that any insult to the tip of a developing bronchus may lead to a different lesion depending on the timing and severity, rather than on the nature, of the insult.

According to Clements and Warner the terms intralobar, extralobar, sequestration and CCAM provide no definite information on the morphology within these lesions. They were the first to suggest considering all anatomical components of the lung involved in the pathological lesion in each particular case. These components are the bronchial airways, the arterial supply and venous drainage, and the lung parenchyma. In a subsequent study the authors confirmed the applicability of this approach on 25 neonates with bronchopulmonary vascular malformations<sup>61</sup>.

With the advent of high-resolution ultrasound technology, coupled with sophisticated Doppler and power Doppler angiography, it is now possible to evaluate fetal arterial<sup>62</sup> and venous systems<sup>63</sup>. We therefore adopted Clements and Warner's classification system with modifications, based on 2D and Doppler ultrasound, and applied it to fetal findings. Clements and Warner<sup>60</sup> originally proposed the term 'malinosculation' (from the Latin: *mal*, abnormal; *in*, in; *osculum*, mouth) to describe the various anatomical combinations. However, this term failed to gain general acceptance. We prefer the term dysplasia<sup>64</sup> (from the Greek: *dis*, abnormal; *plasis*, forming), meaning abnormal tissue formation. We believe the term dysplasia more aptly describes the abnormal development of lung tissue involved in this group of anomalies.

Each unit of the embryonic lung includes a bronchial bud supplied by a systemic capillary plexus derived from the primitive aorta and containing a small branch of the pulmonary artery. The systemic plexus regresses as the growing lung advances and the pulmonary artery develops. We have attempted to assess each lung component involved in the pathology, and group lung dysplasias in the following five categories:

- I. *Agensis of the lung*: includes the most severe dysplasias, wherein the insult is sufficiently early and proximal to the bronchial bud to arrest lung, lobe or lobule development ('wheel' theory Type I).
- II. *Normal lung with abnormal vascular supply*: the bronchial tree continues to develop normally, but pulmonary artery growth is arrested, resulting in normal lung with an isolated segment supplied by persistent systemic vessels instead of the pulmonary artery ('wheel' theory Type III).
- III. *Abnormal lung with abnormal vascular supply*: this includes the 'classic' form of BPS, with disruption to both the airway tract and pulmonary arterial development resulting in systemic arterial supply to abnormal lung parenchyma ('wheel' theory Type IV).
- IV. *Abnormal lung with normal vascular supply*: this category includes bronchogenic cysts and 'classic' CCAM ('wheel' theory Types II, V).
- V. *Miscellaneous*: includes laryngeal atresia with bilateral echogenic lung, split notochord syndrome or bronchopulmonary dysplasia with neuroenteric association.

The novelty of our new classification system is that it enables separate delineation of each fetal lung component involved in the anomaly: the parenchyma, arterial circulation and venous drainage. Further, it is based on prenatal sonographic identification and Doppler flow studies: the arterial supply and venous drainage of the lesions, as opposed to tissue consistency.

In the past, polyhydramnios, mediastinal shift and tumor size were considered bad prognostic factors in fetuses with lung lesions<sup>5-7</sup>. However, all previous studies ignored the lesions' vascular component in their evaluation. We believe that the morphologic description of the lesion as solid or cystic does not affect fetal prognosis,

since the natural course of the entity during gestation is probably influenced primarily by the vascular component of the malformation. The pivotal role of vascular assessment was demonstrated by Clements *et al.* in their clinical study<sup>61</sup> and recently verified in a further original study<sup>65</sup>. The appearance of hydrops fetalis was shown to be the only significant poor prognostic factor in fetuses affected with lung abnormalities<sup>5-7,44,46</sup>. Several possible mechanisms for the development of hydrops fetalis have been suggested. It was postulated that hydrops may be secondary to caval obstruction or cardiac compression from large tumors causing mediastinal shift<sup>66</sup>. This theory has never been verified, and is in fact contradicted by the finding that severe cases of lung anomaly with diaphragmatic hernia do not develop hydrops, despite significant intrathoracic mass.

Other theories have proposed a vascular etiology for hydrops development. Some suggest that overcirculation through the sequestered lung may induce congestive heart failure with resulting hydrops<sup>67</sup>, while others have raised the possibility of twisting of the vascular pedicle resulting in obstruction of the venous and lymphatic drainage<sup>68</sup>. The latter hypothesis has recently been verified in a case report<sup>69</sup>. Postnatal arterial occlusion of the pedicle of a systemic artery led to resolution of lung hyperechogenicity. The authors postulated that venous obstruction causes the hyperechogenicity seen on prenatal ultrasound, probably as a result of blood extravasations into the interstitial space. Similarly, it can be assumed that the mysterious spontaneous regression *in utero* of fetal lung echogenicity may be attributed to relieving such obstruction. Decreased lung overcirculation may also result from decreased placental resistance occurring with advancing gestation. In our accompanying clinical study<sup>12</sup>, we demonstrate the immediate recovery of hemodynamic disturbance in two neonates through arterial embolization, and the regression of fetal hydrothorax with advancing gestational age.

We believe that with state-of-the-art ultrasound equipment and sophisticated Doppler capabilities, *in-utero* evaluation of related vascular anomalies in fetuses with lung dysplasia is now feasible. *In-utero* mapping of significant intrapulmonary shunts and vascular connections may provide better understanding of the pathogenesis of these lesions and improve prenatal management.

It is conceivable that minimal *in-utero* catheterization to alleviate hemodynamic deterioration of fetuses with decompensating lung lesions could shortly be performed.

## SUMMARY

The pathogenesis and *in-utero* classification of fetal lung lesions should be revisited. The proposed use of the term, lung dysplasia, according to the guidelines presented here, accompanied by evaluation of each lung component involved in the lesion, will facilitate classification of fetal lung anomalies. We believe that this simple descriptive approach based on available 2D sonography and Doppler

mapping of vascular anomalies will further improve our understanding of the variability of fetal lung lesions. The applicability of this new classification system to clinical management is presented in the accompanying study.

## REFERENCES

1. Yagel S, Weissman A, Rotstein Z, Manor M, Hegesh J, Anteby E, Lipitz S, Achiron R. Congenital heart defects: natural course and *in utero* development. *Circulation* 1997; 15: 550-555.
2. Yagel S, Achiron R. Developmental fetal malformations: time to change terminology. *Ultrasound Obstet Gynecol* 1998; 11: 89-91.
3. Romero R, Pihu G, Jeanty P, Ghidini A, Hobbins JC. *Prenatal Diagnosis of Congenital Anomalies* Appleton & Lange: Norwalk, CT, 1988; 195-207.
4. Hilpert PL, Pretorius DS. The thorax. In *Diagnostic Ultrasound of Fetal Anomalies Text and Atlas* (1st edn), Nyberg DA, Mahony BS, Pretorius DS (eds). Mosby Year Book: St Louis, MO, 1990; 262-299.
5. Thorpe-Beeston JG, Nicolaidis KH. Cystic adenomatoid malformation of the lung: prenatal diagnosis and outcome. *Prenat Diagn* 1994; 14: 677-688.
6. Adzick NS, Harrison MR, Crombleholme TM, Flake AW, Howell LJ. Fetal lung lesions: management and outcome. *Am J Obstet Gynecol* 1998; 179: 884-889.
7. Laberge JM, Flageole H, Pugash D, Khalife S, Blair G, Filiatrut D, Russo P, Lees G, Wilson RD. Outcome of the prenatally diagnosed congenital cystic adenomatoid malformation: a Canadian experience. *Fetal Diagn Ther* 2001; 16: 178-186.
8. Conran RM, Stocker JT. Extralobar sequestration with frequently associated congenital cystic adenomatoid malformation, Type 2: report of 50 cases. *Pediatr Dev Pathol* 1999; 2: 454-463.
9. Cass DL, Crombleholme TM, Howell LJ, Stafford PW, Ruchelli ED, Adzick NS. Cystic lung lesions with systemic arterial blood supply: a hybrid of congenital adenomatoid malformation and bronchopulmonary sequestration. *Pediatr Surg* 1997; 37: 986-990.
10. MacKenzie TC, Guttenberg ME, Nisenbaum HL, Johnson MP, Adzick NS. A fetal lung lesion consisting of bronchogenic cysts, bronchopulmonary sequestration and congenital cystic adenomatoid malformation: the missing link. *Fetal Diagn Ther* 2001; 16: 193-195.
11. Hendrick HL, Flake AW, Crombleholme TM, Howell LJ, Johnson MP, Wilson RD, Adzick NS. History of fetal diagnosis and therapy: Children's Hospital of Philadelphia Experience. *Fetal Diagn Ther* 2003; 18: 65-82.
12. Achiron R, Zalel Y, Lipitz S, Hegesh J, Mazkereth R, Kuint J, Jacobson J, Yagel S. Fetal lung dysplasia: clinical outcome based on a new classification system. *Ultrasound Obstet Gynecol* 2004; 24: 127-133.
13. Chin KY, Tang MY. Congenital adenomatoid malformation of one lobe of a lung with general anasarca. *Arch Pathol* 1949; 48: 221-229.
14. Kwittken J, Reiner L. Congenital cystic adenomatoid malformation of the lung. *Pediatrics* 1962; 30: 759-763.
15. Stocker JT, Madewell JE, Drake RM. Congenital cystic adenomatoid malformation of the lung. A classification and morphologic spectrum. *Hum Pathol* 1977; 8: 155-171.
16. Stocker JT. Congenital and developmental diseases. In *Pulmonary Pathology* (2nd edn), Dial DH, Hammer SP (eds). Springer: New York, NY, 1994; 174-180.
17. Pryce DM. Lower accessory pulmonary artery with intralobular sequestration of lung: a report of seven cases. *J Pathol* 1946; 58: 457-467.
18. Sade RM, Clouse M, Ellis FH. The spectrum of pulmonary sequestration. *Ann Thorac Surg* 1974; 18: 644-655.

19. Gerle RD, Jaretzki A, Ashley CA, Berne AS. Congenital bronchopulmonary foregut malformations. *N Engl J Med* 1968; 276: 1413–1419.
20. Hutchin P. Congenital cystic disease of the lung. *Rev Surg* 1971; 28: 79–87.
21. Stocker JT. Sequestration of the lung. *Semin Diagn Pathol* 1986; 3: 106–121.
22. Skandalakis JE, Gray SW, Symbas P. Pulmonary circulation. In *Embryology for Surgeons: The Embryological Basis for the Treatment of Congenital Anomalies* (2nd edn), Skandalakis JE, Gray SW, Symbas P (eds). Williams & Wilkins: Baltimore, MD, 1994; 463–470.
23. Savic B, Birtel FJ, Tholen W. Lung sequestration: report of seven cases and review of 540 published cases. *Thorax* 1979; 34: 96–101.
24. Lager DJ, Kuper KA, Haake GK. Subdiaphragmatic extralobar pulmonary sequestration. *Arch Pathol Lab Med* 1991; 115: 336–338.
25. Curtis MR, Mooney DP, Vaccaro TJ, Williams JC, Cendron M, Shorter NA, Sargent SK. Prenatal ultrasound characterization of the suprarenal mass: distinction between neuroblastoma and subdiaphragmatic extralobar pulmonary sequestration. *J Ultrasound Med* 1997; 16: 75–83.
26. Kousseff BG, Gilbert-Barness E, Debich-Spicer D. Bronchopulmonary-foregut malformations: a continuum of paracrine hamartomas? *Am J Med Genet* 1997; 68: 12–17.
27. Craig JM, Kirkpatrick J, Neuhauser EBD. Congenital cystic adenomatoid malformation of the lung in infants. *Am J Radiol* 1956; 76: 516–526.
28. Dempster AG. Adenomatoid hamartoma of the lung in the neonate. *J Clin Pathol* 1969; 22: 401–406.
29. Ostor AG, Fortune DW. Congenital cystic adenomatoid malformation of the lung. *Am Clin Pathol* 1978; 70: 595–604.
30. Moreman P, Fryns JP, Vandenberghe K, Devlieger H, Lauweryns JM. Pathogenesis of CCAM of the lung. *Histopathology* 1992; 21: 315–321.
31. Cangiarella J, Greco MA, Askin F, Perlman E, Goswami S, Jagirdar J. Congenital cystic adenomatoid malformation of the lung: insights into the pathogenesis utilizing quantitative analysis of vascular marker CD34 (QBEND-10) and cell proliferation marker MIB-1. *Mod Pathol* 1995; 8: 913–918.
32. Sakamoto K, Nagai A, Ueno H, Matsumiya H. Cellular proliferation of pre and postnatal lung cells in the mouse (Abstract) *Am Rev Respir Dis* 1991; 143: A500.
33. Cass DL, Quinn TM, Yang EY, Liechty KW, Crombleholme TM, Flake AW, Adzick NS. Increased cell proliferation and decreased apoptosis characterize congenital cystic adenomatoid malformation of the lung. *J Pediatr Surg* 1998; 33: 1043–1046.
34. Fromont-Hankard G, Philippe-Chomette P, Delezoide AL, Nessmann C, Aigrain Y, Peuchmaur M. Glial cell-derived neurotrophic factor expression in normal human lung and congenital cystic adenomatoid malformation. *Arch Pathol Lab Med* 2002; 126: 432–436.
35. Liechty KW, Crombleholme TM, Quinn TM, Cass DL, Flake AW, Adzick NS. Elevated platelet-derived growth factor-B in congenital cystic adenomatoid malformations requiring fetal resection. *J Pediatr Surg* 1999; 34: 805–809.
36. Fraser RG, Pare JAP. Pulmonary abnormalities of developmental origin. In *Diagnosis of Diseases of the Chest* (2nd edn), W B Saunders: Philadelphia, PA, 1977; 602–628.
37. Wigglesworth JS. Pathology of the lung in the fetus and neonate, with particular reference to problems of growth and maturation. *Histopathology* 1987; 11: 671–689.
38. Hutchin P, Friedman PJ, Saltzstein SL. Congenital cystic adenomatoid malformation with anomalous blood supply. *J Thorac Cardiovasc Surg* 1974; 62: 220–225.
39. Stovin PGI. Early lung development. *Thorax* 1985; 40: 401–404.
40. Haddon MJ, Bowen AD. Bronchopulmonary and neuroenteric forms of foregut anomalies. *Radiol Clin North Am* 1991; 29: 241–254.
41. Hubbard AM, Crombleholme TM. Anomalies and malformations affecting the fetal/neonatal chest. *Sem Radiol* 1998; 23: 117–125.
42. Dhingsa R, Coakley FV, Albanese CT, Filly RA, Goldstein R. Prenatal sonography and MR imaging of pulmonary sequestration. *AJR Am J Roentgenol* 2003; 180: 433–437.
43. Sauerbrei E. Lung sequestration. Duplex Doppler diagnosis at 19 weeks' gestation. *J Ultrasound Med* 1991; 10: 101–105.
44. Adzick NS, Harrison MR, Glick PL, Globus MS, Anderson RL, Mahony BS, Callen PW, Hirsch JH, Luthy DA, Filly RA. Fetal cystic adenomatoid malformation: prenatal diagnosis and natural history. *J Pediatr Surg* 1985; 20: 483–488.
45. Bale PM. Congenital cystic malformation of the lung: a form of congenital bronchiolar (adenomatoid) malformation. *Am J Clin Pathol* 1979; 71: 411–420.
46. Bunduki V, Ruano R, da Silva MM, Miguez J, Miyadahira S, Maksoud JG, Zugaib M. Prognostic factors associated with congenital cystic adenomatoid malformation of the lung. *Prenat Diagn* 2000; 20: 459–464.
47. Achiron R, Strauss S, Seidman DS, Lipitz S, Mashich S, Goldman B. Fetal lung hyperechogenicity: prenatal ultrasonographic diagnosis, natural history and neonatal outcome. *Ultrasound Obstet Gynecol* 1995; 6: 40–42.
48. Langer B, Donato L, Reithmuller C, Becmeur F, Dreyfus M, Favre R, Schlaeder G. Spontaneous regression of fetal pulmonary sequestration. *Ultrasound Obstet Gynecol* 1995; 6: 33–39.
49. Lopoo JB, Goldstein RB, Lipshutz GS, Goldberg JD, Harrison MR, Albanese CT. Fetal pulmonary sequestration: a favorable congenital lung lesion. *Obstet Gynecol* 1999; 94: 567–571.
50. Choong KKL, Trudinger B, Chow C, Osborn RA. Fetal laryngeal obstruction: sonographic detection. *Ultrasound Obstet Gynecol* 1992; 2: 357–359.
51. Hirose R, Suita S, Taguchi T, Koyanagi T, Nakano H. Extralobar sequestration mimicking cystic adenomatoid malformation in prenatal sonographic appearance and histological findings. *J Pediatr Surg* 1995; 30: 1390–1393.
52. Rashad F, Grisoni E, Gaglione S. Aberrant arterial supply in congenital cystic adenomatoid malformation of the lung. *J Pediatr Surg* 1988; 23: 1007–1008.
53. Aulicino MR, Reis ED, Dolgin SE, Unger PD, Shan KD. Intra-abdominal pulmonary sequestration exhibiting congenital adenomatoid malformation: report of a case and review of the literature. *Arch Pathol Lab Med* 1994; 118: 1034–1037.
54. Case Records of Massachusetts General Hospital (case 36–1999). *N Engl J Med* 1999; 341: 1680–1685.
55. MacGillivray TE, Harrison MR, Goldstein RB, Adzick NS. Disappearing fetal lung lesions. *J Pediatr Surg* 1993; 28: 1321–1325.
56. Culiner MM. Intralobar bronchial cystic disease, the “sequestration complex” and cystic bronchiectasis. *Dis Chest* 1968; 53: 462–469.
57. Buntain WL, Isaacs H, Payne VC, Lindesmith G, Rosenkrantz JG. Lobar emphysema, cystic adenomatoid malformation, pulmonary sequestration, and bronchogenic cyst in infancy and childhood: a clinical group. *J Pediatr Surg* 1974; 9: 85–93.
58. Demos JN, Teresi A. Congenital lung malformations. A unified concept. *J Thorac Cardiovasc Surg* 1975; 70: 260–264.
59. Heitzman ER. *The Lung: Radio-pathologic Correlations Anomalies of Pulmonary Parenchymal and Peripheral Vascular Development: The Sequestration Spectrum* (2nd edn), CV Mosby: Philadelphia, PA, 1984; 17–38.
60. Clements IS, Warner JO. Pulmonary sequestration and related congenital bronchopulmonary vascular malformations: nomenclature and classification based on anatomical and embryological considerations. *Thorax* 1987; 42: 401–408.
61. Clements BS, Warner JO, Shinebourne EA. Congenital bronchopulmonary vascular malformations: clinical application of a simple anatomical approach in 25 cases. *Thorax* 1987; 42: 409–416.

62. Sivan E, Rotstein Z, Lipitz S, Sevillia J, Achiron R. Segmentary fetal branch pulmonary artery blood flow velocimetry: *in utero* Doppler study. *Ultrasound Obstet Gynecol* 2000; **16**: 453–456.
63. Achiron R, Hegesh J, Yagel S, Lipitz S, Cohen SB, Rotstein Z. Abnormalities of the fetal central veins and umbilico-portal system: prenatal ultrasonographic diagnosis and proposed classification. *Ultrasound Obstet Gynecol* 2000; **16**: 539–548.
64. Wolf SA, Hertzler JH, Philippart AI. Cystic adenomatoid dysplasia of the lung. *J Pediatr Surg* 1980; **15**: 925–930.
65. Lee ML, Tsao LY, Chaou WT, Yang AD, Yeh KT, Wang JK, Wu MH, Lue HC, Chiu IS, Chang CI. Revisiting congenital bronchopulmonary vascular malformations: a haphazard branching theory of malinosculature and its clinical classification and implication. *Pediatr Pulmonol* 2002; **33**: 1–11.
66. Rice HE, Estes JM, Hedrick MH, Bealer JF, Harrison MR, Adzick NS. Congenital cystic adenomatoid malformation: a sheep model. *J Pediatr Surg* 1994; **29**: 692–696.
67. Thomas CS, Leopold GR, Hilton S, Key T, Coen R, Lynch F. Fetal hydrops associated with extralobar pulmonary sequestration. *J Ultrasound Med* 1986; **5**: 668–671.
68. Hernanz-Schulman, Stein M, Neblett WW, Atkinson JB, Kirchner SC, Heller RM. Pulmonary sequestration diagnosis with color Doppler sonography and a new theory of associated hydrothorax. *Radiology* 1991; **180**: 817–821.
69. Morville P, Malo-Ferjani L, Graesslin O, Bory JP, Harika G. Physiology, hypothesis and treatment of pulmonary sequestration. *Am J Perinatol* 2003; **20**: 87–89.



Pneumothorax Lung ultrasound is a sensitive and specific technique for identifying pneumothorax, including the occult form, and for guiding chest drainage as an emergency life-saving procedure. The diagnosis of pneumothorax traditionally has been based on chest radiography. Although up to 50% of cases can only be detected using HR-CT, that is not the case using plain chest radiography because of anterior air collection [68]. In this setting, lung ultrasound provides much better accuracy for the early detection of pneumothorax. Sonographically, in pneumonia, the lungs typically exhibit two key ultrasound signs, B-lines and consolidation [72-73]. The pneumonic infiltrate presents itself as low-echo structures with irregular borders and inhomogeneous echo texture [74]. New classification based on pathogenesis, two-dimensional and color Doppler ultrasound. *Ultrasound Obstet Gynecol.* 2004 Aug;24(2):107-14. doi: 10.1002/uog.1110. Authors. R Achiron, J Hegesh, S Yagel. PMID: 15287045. DOI: 10.1002/uog.1110. No abstract available. Publication types. Lung US is a comparatively recent addition to emergency US. Its systematic use was first described by Lichtenstein in his textbook "General ultrasound in the critically ill" (Springer, 2002). Since then, critical care doctors and respiratory physicians worldwide have taken it up for a number of indications including: Diagnosis of: Pleural fluid & pleural disease. If the areas of diseased alveolar tissue abut the pleura, these areas are no longer invisible on LUS, but become dark (sonolucent). Classically they appear as irregular, dark areas on LUS. (Figure 16). Experienced scanners use Doppler imaging to differentiate some conditions based on their vascularity, for example: Pneumonia: normal vascularity preserved. Malignancy: bizarre vascularity / areas of necrosis.